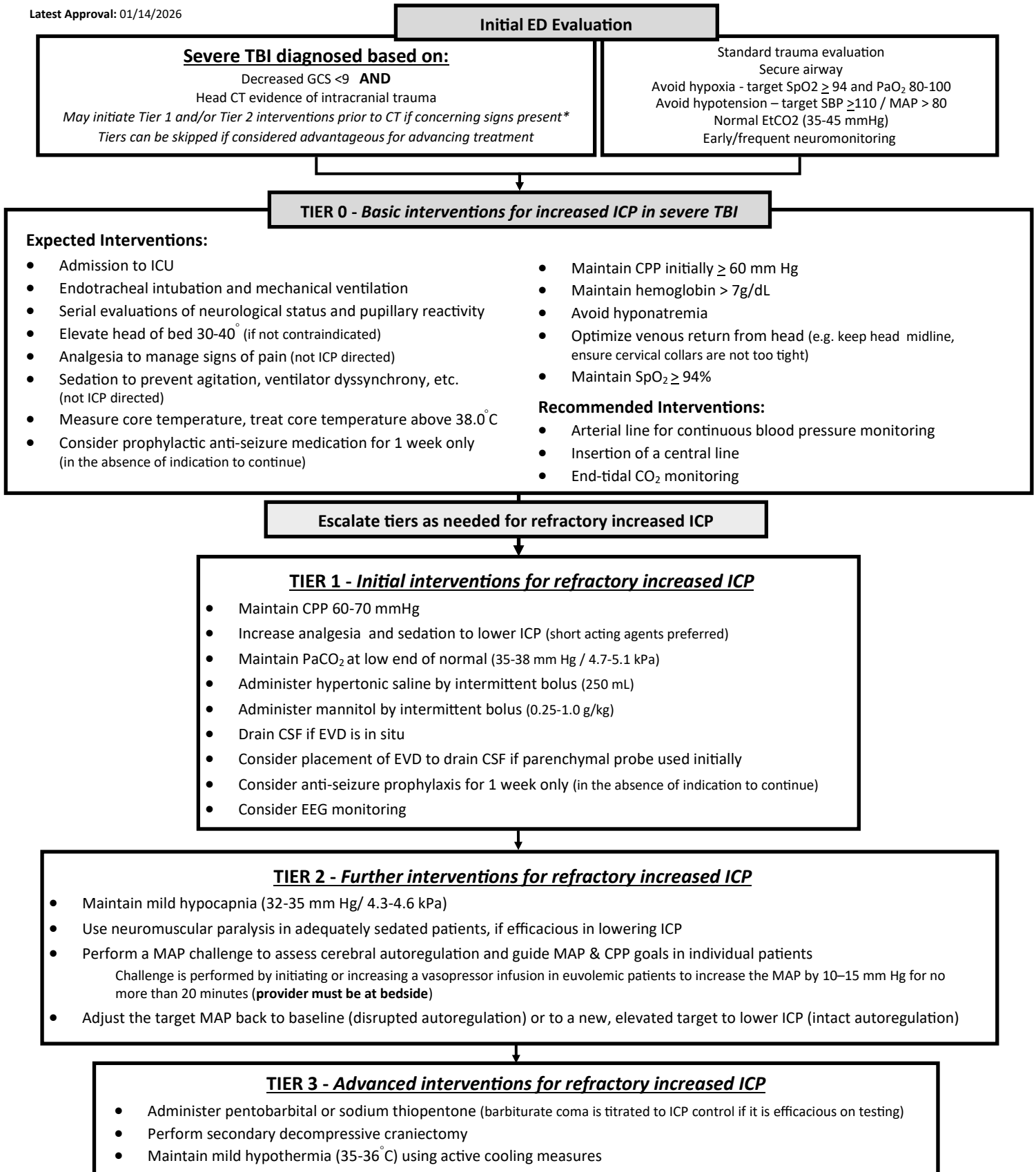


# Clinical Practice Guideline (CPG) Management of Increased ICP in Severe TBI



**\*Signs of Herniation**

1. Dilated/nonreactive/asymmetric pupils
2. Motor exam with extensor posturing
3. Progressive/rapid neurologic deterioration
4. Ipsilateral pupillary dilation with contralateral hemiparesis
5. Cushing’s Triad (bradycardia, hypertension, Cheyne-Stokes breathing)

**References:**

Alam HB, Vercruyse G, Martin M, et al. Western Trauma Association critical decisions in trauma. *Journal of Trauma and Acute Care Surgery*. 2020;88(2):345-351. doi:10.1097/a.0000000000002555

ACS TQIP. (2024). *BEST PRACTICES in the MANAGEMENT of TRAUMATIC BRAIN INJURY*. [https://www.facs.org/media/mkej5u3b/tbi\\_guidelines.pdf](https://www.facs.org/media/mkej5u3b/tbi_guidelines.pdf)