

Clinical Practice Guideline (CPG) Blunt Cerebrovascular Injury (BCVI) Diagnosis and Management

Original Date: 1/2016

Latest Approval: 01/13/2026

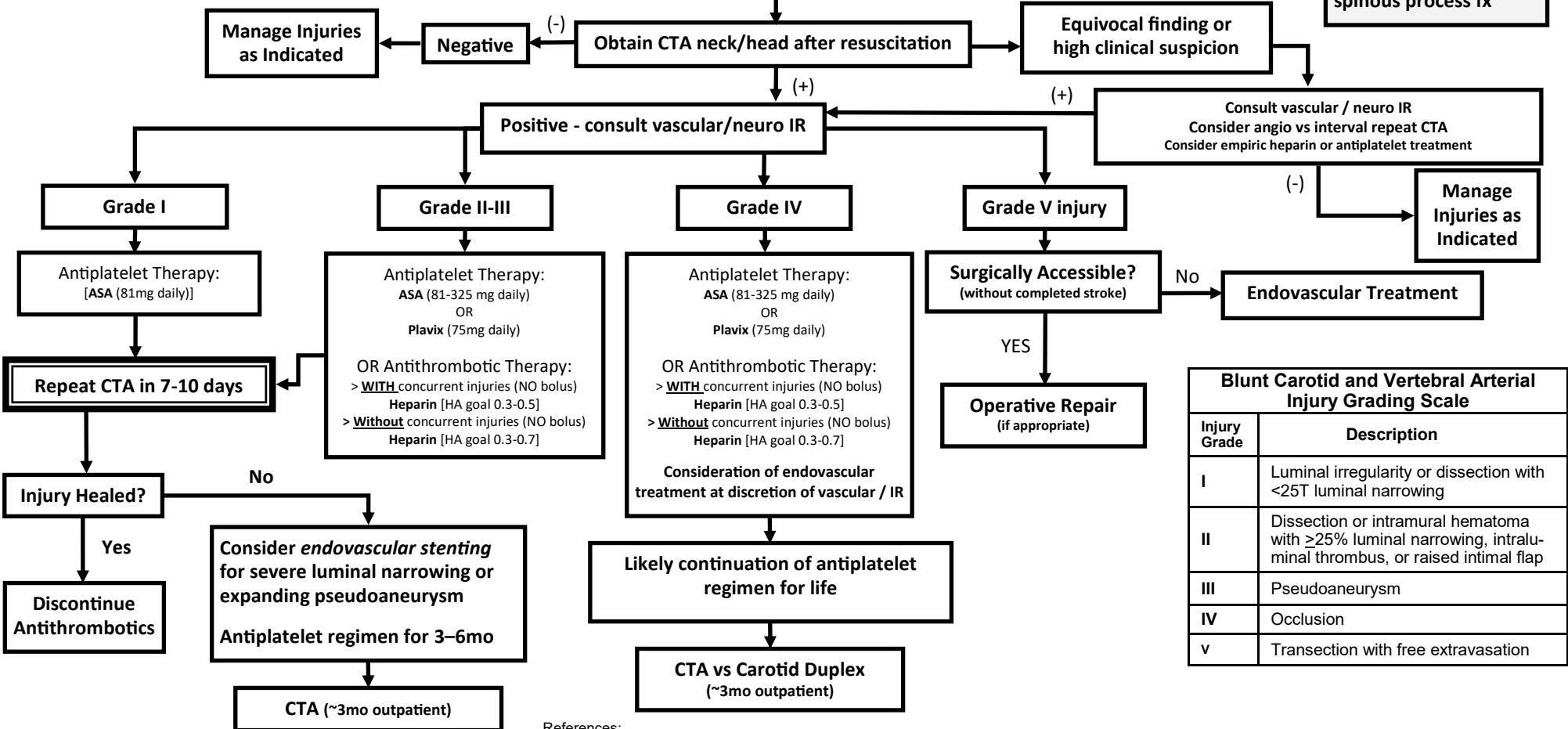
Trauma patient presents with signs or symptoms of BCVI OR **Has a high risk factor for BCVI with high-energy mechanism:**

- Focal neuro deficit (TIA, hemiparesis, vertebrobasilar symptoms, Horner's Syndrome)
- Arterial hemorrhage (nose, mouth, neck)
- Cervical bruit in pts <50 yo
- Expanding neck hematoma
- Neurologic deficit inconsistent with Head CT
- CVA on follow-up CT or MRI (not present on initial)

- LeForte II & III fx
- Mandible fx
- Upper rib fx
- Cervical vertebral body or transverse foramen fx, subluxation, or ligamentous injury at any level*
- Complex skull/occipital condyle fx
- Basilar skull fx w/carotid canal involvement
- TBI w/ GCS <6 or TBI w/ thoracic injuries
- Near hanging with anoxic brain injury
- Clothesline type injury or seat belt abrasion with significant swelling, pain, or altered MS
- Scalp degloving
- Thoracic vascular injuries
- Blunt cardiac rupture

Physician clinical judgement supersedes this guideline

***Excluding isolated transverse process or spinous process fx**



Injury Grade	Description
I	Luminal irregularity or dissection with <25T luminal narrowing
II	Dissection or intramural hematoma with ≥25% luminal narrowing, intraluminal thrombus, or raised intimal flap
III	Pseudoaneurysm
IV	Occlusion
V	Transection with free extravasation

References:
 Biff WL, Cothorn CC, Moore EE, et al. Western Trauma Association Critical Decisions in Trauma: Screening for treatment of blunt cerebrovascular injuries. J. Trauma 2009; 67: 550-1153
 Brombert WJ, Collier BC, Diebel LN, et al. Blunt cerebrovascular injury practice management guidelines: The Eastern Association for the surgery of trauma. J. Trauma. 2010; 68: 471-477
 Geddes, Burlew CC et al, Am J Surg. 2016
 UpToDate (2026). Blunt cerebrovascular injury: Treatment and outcomes. UpToDate. <https://www.uptodate.com/contents/blunt-cerebrovascular-injury-treatment-and-outcomes#H4127176185>